



# Ita. J. Sports Reh. Po.

Italian Journal of  
Sports Rehabilitation and Posturology

## Swallowing and the attitude of the neck/body !



Authors: Jan van de Rakt <sup>1</sup>,



Steve McCarthy-Grunwald <sup>2</sup>.

<sup>1</sup> Physical Therapist NDT teacher IBITA, Course Leader and teacher on the Dutch Institute for Allied Health Sciences. Nursing Home "Waelwick" in Ewijk. The Netherlands

<sup>2</sup> MSc BSc RMN Senior Lecturer in Mental Health Nursing with Dementia Specialty. University of Cumbria, Bowerham Road, Lancaster, LA1 3JD England



## Abstract

What has swallowing to do with the trunk position and the muscle pattern such as the diagonals of our body? Severe stroke patient have sometimes an damage in the greater swallowing center and must try the other smaller to activate to restore an swallowing function. This group of stroke patient has often balance problems in the sitting position even sometimes with the lying position and will use even the power of the neck to correct there position. When the situation was so very difficult the back diagonal will ask for an neck extension to fixated the upper body. The lower body will than have two extension synergy that fixated the leg against each other but that gives not the best balance , only an stabilization of the body.. The back diagonal than are very small, not from hip ( trochanter major) to the shoulder but from hip ( trochanter minor) to the shoulder blade inside and now is the neck-activity very important for trunk stabilization. The angle in the back diagonal on pelvis level is than very great and the tone is concentrated around the spine. By an stroke patient will be always an asymmetrical tone and that can give an fixed head position in lateroflexion /rotation and extension even caused an static general reaction (A.T.N.R.) but also an asymmetrical muscle tone on the front of the neck and that can cause an deviation of the tongue bone and makes swallowing impossible. Research what the relation is between head position and swallowing is available for older with dementia , and for stroke /brain-damage . In the Nursing Home “Waelwick “ we have special interest in this part of trunk stabilization, transfers and swallowing possibilities with an very clear goal: “ The head position is very important to restore the swallowing possibilities and must therefore be no part of the stabilization when person sit or lie in bed, even the transfers must done without an extreme nek extension. That is not only the task of the speech therapist or the nurse but that must be teamwork !! **Study Design.** A research study. **Authorship credit :** “Criteria authorship scientific article” has been used “Equal Contribution” (EC). **Citation.;** Jan van de Rakt , Steve McCarthy-Grunwald , Swallowing and the attitude of the neck/body ! ; Ita. J. Sports Reh. Po. 2021; 8 (17); 2; 1; 1745 - 1783 ; DOI: 10.17385/ItaJSRP.21.17.080201 ; ISSN 2385-1988 [online] ; IBSN 007-111-19-55; CGI J OAJI 0,101]. Published online.

**Keywords;** dysphagia, swallowing , trunk , tongue bone, diagonals.

### Introduction.

Swallowing is a very complex function in which the brain has a great area for the perception and the motoric. And that not only on one side but on both side but only one side is complete, the other has less possibilities.

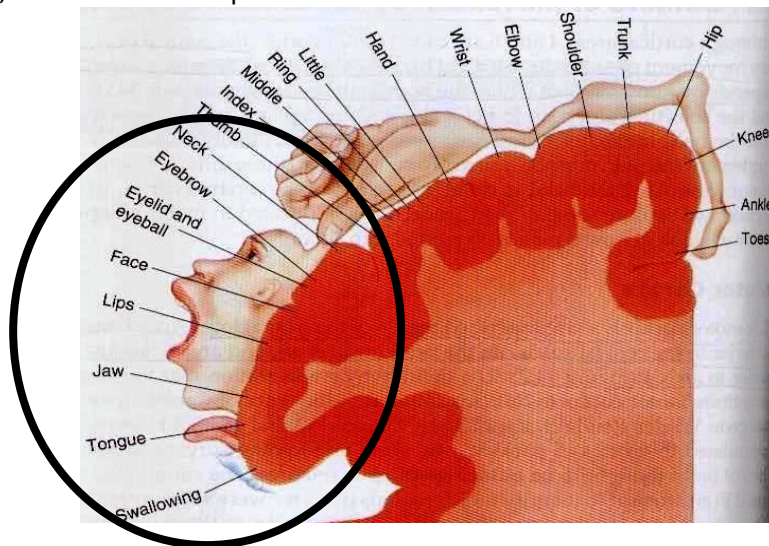


Figure 1

**Figure 1** . The circle give the area that has an direct influence on the swallowing performance and swallowing centre is base. But less control in other are4a will have influence on the smoothness of the swallowing, eating etc. process.

(Figure 1 published with the responsibility and permission of the author by j.v.d.Rakt.)

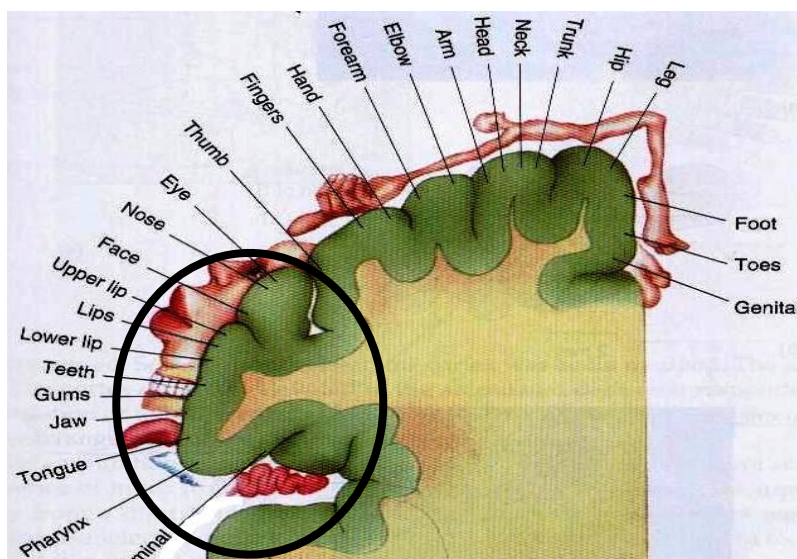


Figure 2

**Figure 2**. This gives the cortex and his motoric area that are involved directly with the swallowing process and again this isn't only the "reflex" system.

Figure 2 published with the responsibility and permission of the author by j.v.d.Rakt.)

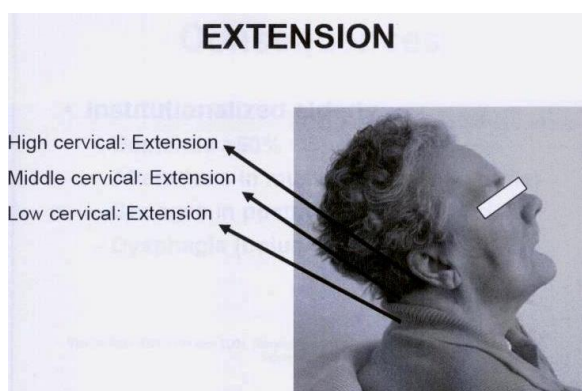
In Figure 1 we see swallowing on the left side under but the area that is involved with the swallowing procedure start by the lips (circle). The involvement of the neck, trunk and also the hip is also present.

In figure 2 has for an good swallowing act the need that the tongue can do his job and that depend directly from the tone of the neck on the front and the back and that depend again from the attitude of the trunk.

Certainly swallowing can be damage by the stroke and then this patient must learn to use the other lesser centre, but severe stroke patient have also an body out of balance and that can give that there is more tone on one side and that there is an asymmetrical attitude or more tone on the back than on the front. The diagonal and the static reaction that are needed to control the posture and create an optimal mobility for the neck are writing in this articles [1,2,3]

Prof. I. Baumans and his team[4] (VU Brussels) did an investigation by patient osteoporosis that had an restriction of movement in the neck region and did an intervention with mobilization [7]and investigated what this had for difference in the swallowing capacity. It is an privilege that we can quote out this article to give an good picture what the treatment was and which result they obtain. In this investigation it was loss of mobility, but when restoration of this mobility loss has such an great impact we must also look to all person with tone differences, because that will lead to loss of mobility and an worse swallowing function[5,8] This were mobilization loss but stroke patient have often restriction of movement through the high tone and that can lead to changes in joint structures and that can lead to an movement restriction. Three types of movement restriction in the neck he treated in his investigation[5], and the loss of mobility was caused by osteoporosis, but the reason can also be an paratonia because this investigation was done by elderly with an cognitive impairment and there is evidence that there is also an increase of tone [9];

- Type A with an restriction to flexion of the neck



**Photo 1**

Restriction type A;

An extension in the neck high cervical.

This restriction is also know by people with Parkinson disease and severe Stroke patient.

But then the restriction is often only tone or an combination of tone, joint and even nerves[10].

*Photo 1* published with the responsibility and permission of the author by j.v.d.Rakt.)

**Photo 1**

- Type B with an restriction cervico – thoracic




## Kyphotic

High cervical: Flexion

Middle cervical: Flexion

Low cervical: Flexion



### Photo 2

Restriction type B in the cervical –thoracic spine.

Here is the thoracic spine often through osteoporosis not so stable anymore and cannot give the best base for the cervical part of the spine. But also an pelvis stand backward will give an collapse of the thoracic spine and will decrease the stable base for the cervical spine [11,12,13]

Photo 2 published with the responsibility and permission of the author by j.v.d.Rakt.)

1749

Photo 2

Both restriction will have influence on the front of the neck and that gives difficulties for the muscles there to do their job in the swallowing procedure.

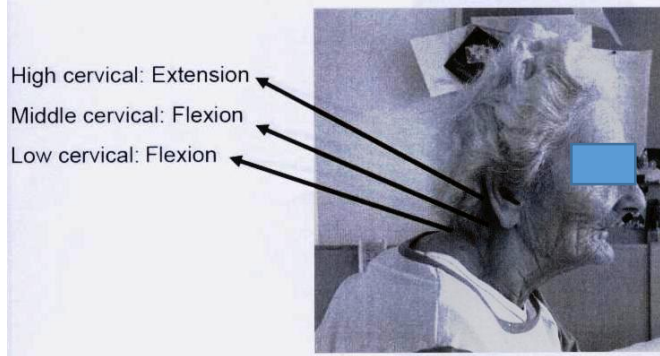
- Type C antero- position

## ANTEROPOSITION

High cervical: Extension

Middle cervical: Flexion

Low cervical: Flexion



### Photo 3

Restriction Type C , the antero-position.

The difference her is that the cervical spine is capable to counter the collapse of the thoracic spine [11.12].

What wasn't possible by type B is here still possible and here the base of the sitting attitude is very essential .

Photo 3 published with the responsibility and permission of the author by j.v.d.Rakt.)

Photo 3

The treatment of the restriction occur with an manipulation [7] with an great amount of tactile stimulation and always some traction on the vertebrae[14,15].



1750

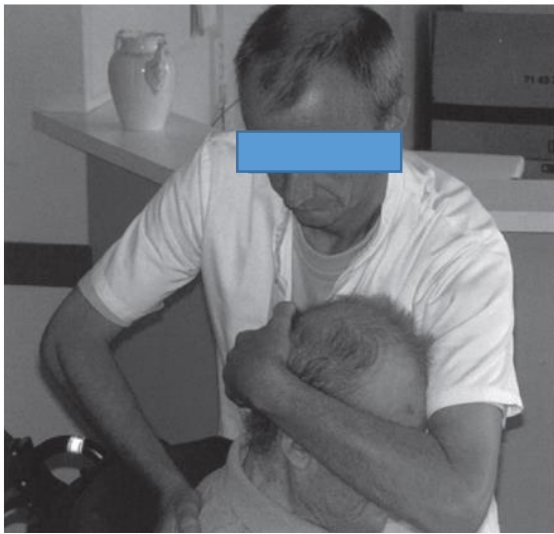

Photo 4

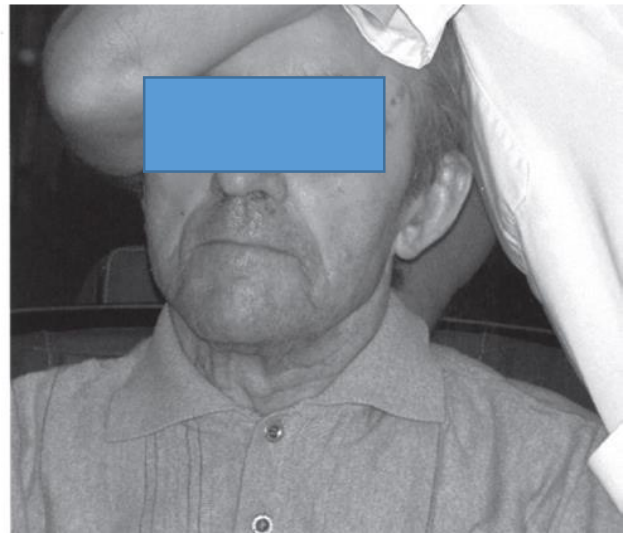


Photo 5

**Photo 4 and 5** give an view what for an kind of manual treatment was use to improve the mobility of the cervical spine.  
 This treatment was done by al the three type of the position of the cervical spine with their restriction.  
 In this article the loss of mobility stand central and that loss of mobility was primary an joint problem.  
 Photo 4 and 5 published with the responsibility and permission of the author by j.v.d.Rakt.)

The result of the investigation were impressive !  
 After one session was there an improvement but after an week this was significant. The improvement of the mobility has also an significant effect on the swallowing performance of the treated people.

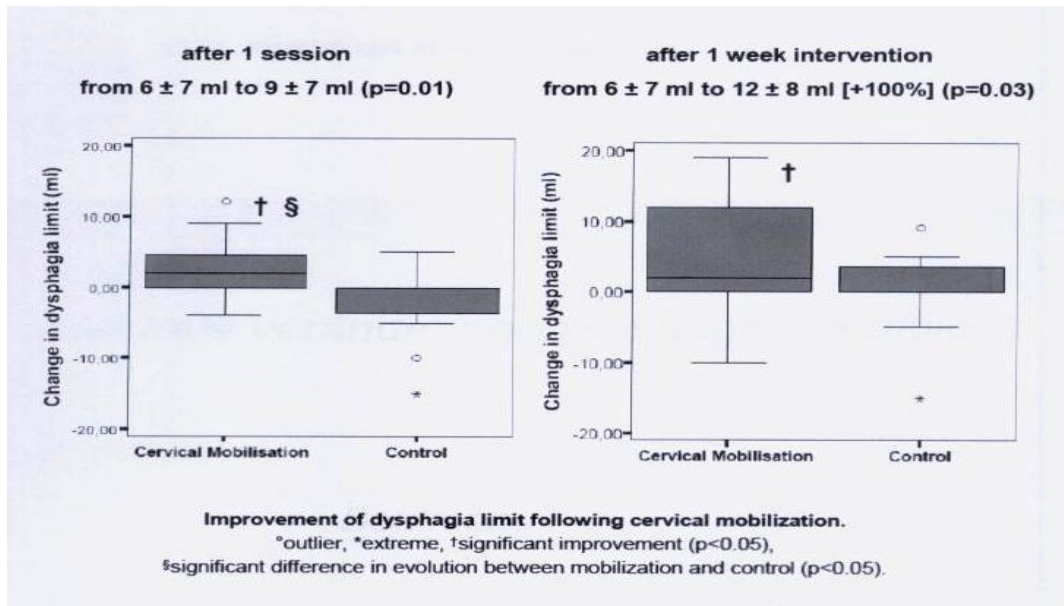


Table 1



**Table 1**

The measurement were taken after one session (left) and after 1 week intervention ( right) and the result after an week are impressive. But after 1 session is an increase mobility directly improving the swallowing ability !!

Table 1 published with the responsibility and permission of the author by j.v.d.Rakt.and with thanks on Y.Bautmans and his group.

1751

This investigation has proved that the mobility of the cervical spine has an direct correlation with possibilities of the muscles on the front of the neck that provide the swallowing procedure. By the group of people in this investigation was the swallowing center in the brain not directly damaged but “normal” according their age.

This investigation is not done by patient with neurological diseases but out the practice we know that swallowing is often an problem by stroke-, Parkinson and individuals with dementia and that this isn't only caused by the brain damage directly in the swallowing center. And when that center is damaged than will often the cervical spine will be an problem and must we try to mobilize the spine optimal because that has an major effect on the rest possibilities of the swallowing performance.

The attitude with extension cervical and the antero- position will be observed in nursing home very often. There we see the groups that have so bad trunk attitude.

That can an struggle to get this position in the chair optimal and asked for an continue extension of the neck to hold control- “extension” type A, but then with an high tone that makes the restriction in the cervical spine [13,16].

Or the pelvis in turned to the back and gives an collapse of the thoracic. And that asked for an counter movement of the cervical spine to stabilized the attitude- Antero –position Type C.

Or when the attitude isn't possible because the cervical extension isn't capable to counter that there will be an collapse also of the cervical spine and must the whole attitude go more to the back and is moving for this individual in an sitting position almost impossible.

All three of type will have an effect on the performance of the muscle on the front of the neck.

And the problem is now not directly an mobility loss in the cervical spine but an action of all trunk muscle to stabilized the attitude because the base isn't well enough.

That will change the muscle performance that are important by eating etc.

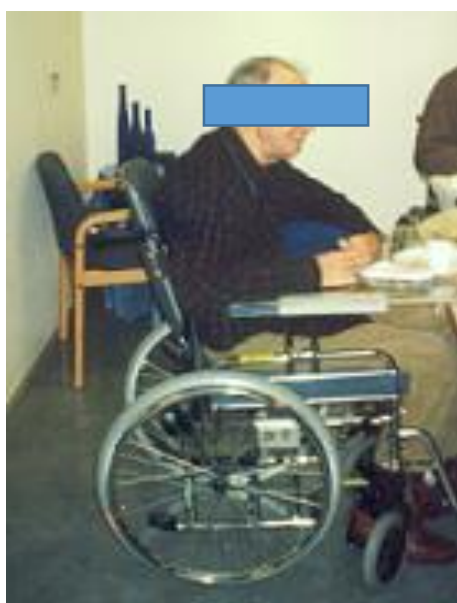

Photo 6



Photo 7

**Photo 6 and 7.**

Stroke patient with the affected side on the left and with a low tone. Posture in the wheelchair with the pelvis rotated to the back, the thorax spine in flexion and the head must now go to the back to stabilize the posture and you have an antero-position. (Type C) Photo 7 gives an picture on the end of the day, look to his M. Cleidomastoideus and on both photo the mouth stand open.

It isn't normal that the mouth stand open, we see this only when people had so much neck extension, that opening of the mouth is done by the muscle on the front to allow that amount of extension in the neck.

Observe further that the tongue lies in the lower jaw.

This are both symptoms that are important to recognize when we treat this people to improve the eating and swallowing performance.

*Photo 6 and 7 published with the responsibility and permission of the author by j.v.d.Rakt.)*

**Our investigation:**

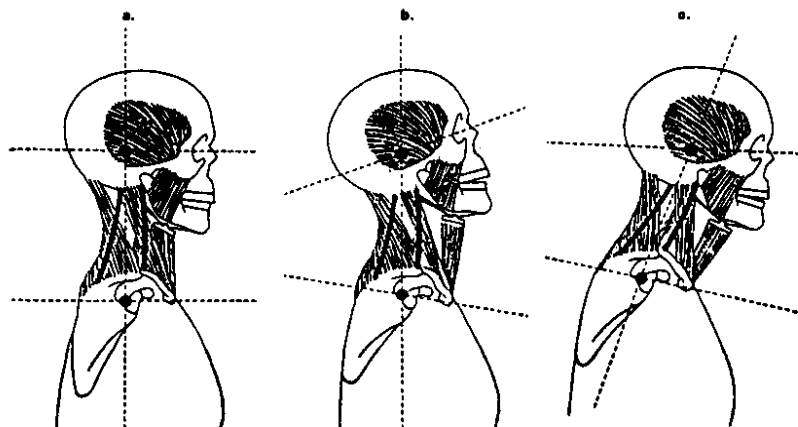
Because there was no investigation that has try to find out of this maybe also happen by nursing home patient with neurological diseases, we decided to do it our self.

Therefore we collected all patient that ;

1. Had difficulty with swallowing.
2. That - especially- on the dementia ward - eat almost never there plate empty.

And we investigated;

1. The mobility of the neck.
2. The tone of the neck muscle and the tone off the muscle on the neck to shoulder. On the back also because an upper trunk backward with elevation can give an change in the position of the cervical vertebrae and therefor an restriction.
3. The sit position
4. The mobility and the position of the tongue bone. Test of the mobility in all directions but the most important issue was the smoothness of movement in sideways direction.
5. The possibilities of mouth closure and when this mouth was open where was the tongue placed and how was there the tone.
6. And the tone of the muscle on the front by the three types of head position as investigated in the article [4]



**Figure 4**



**Figure 4**

This figure was used as an example to recognize a different head posture and was this recognized we investigated the other elements.

In the first part on the left is the anatomic situation draw that give an normal head attitude.

The mid drawing gives an example of type A , full extension of the head.

The drawing on the right is an example of type C , antero –position.

Figure 4 published with the responsibility and permission of the author by j.v.d.Rakt.).

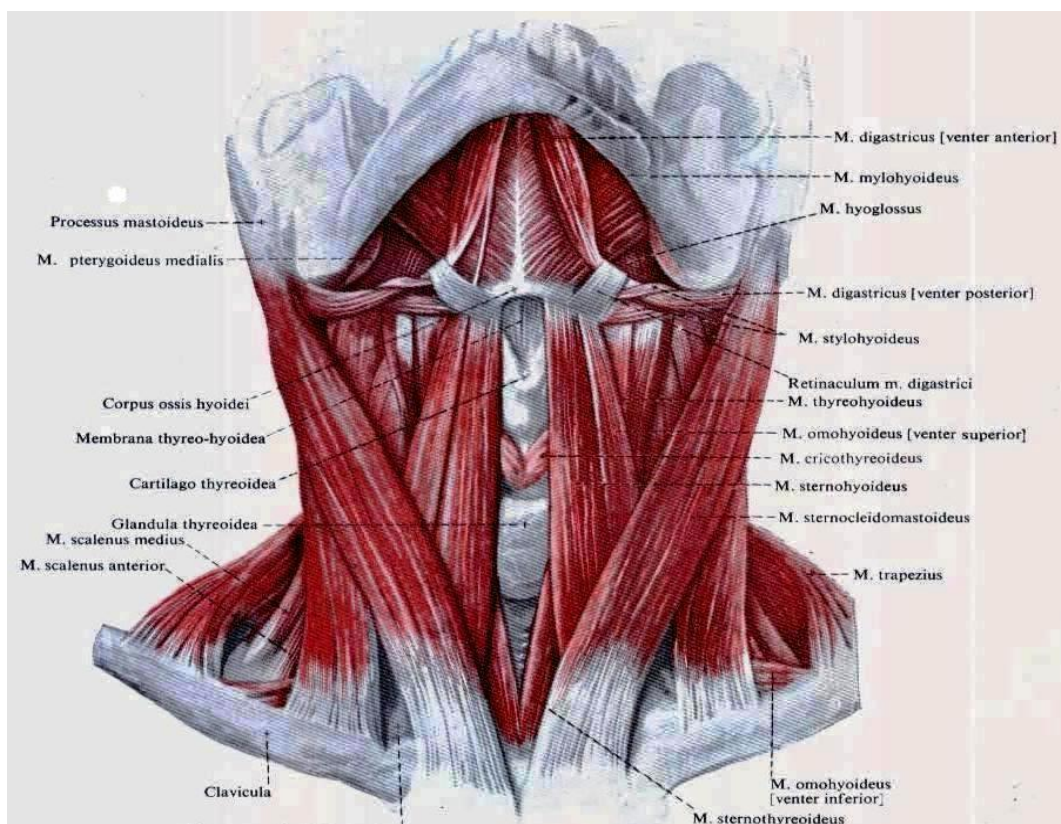
1753

There ( Mid part of figure 4) create an short cervical spine, that elongated the muscles and structures on the front of the neck. What will happen is clear. To get the muscle without much action in an better situation the mouth goes open and the tongue bone is transverse to an more anterior position. This will decrease the stretch tone on the muscle on the front.

We see therefore an mouth that is open en an replacement of the tongue bone to the front, this position change makes swallowing more difficult already, therefore the question when this attitude is always so what will happen not only with the swallowing possibilities but also with the muscles on the front and back and of course ; “Why is this active extension of the neck necessary” !!

The antero-position seems to have an solution for the great amount of extension in the cervical spine but that isn't the case. Again there is an increased tone and power in the cervical spine muscle on the back and an stretch on the muscle on the front, with again an different position of the tongue bone and the mouth open.

The same question can we place here!!

**Figure 5**



**Figure 5**

Muscle on the front of the neck.

Corpus ossis hyoidei is the tongue bone and under the tongue bone we see the membranes who goes to the trachea.

That means that the tongue bone has an connection directly ( without muscle ) with the trachea.

Furthermore the great number of small muscle that is symmetrical left and right beside that central part the tongue bone membrane and trachea !

Figure 5 published with the responsibility and permission of the author by j.v.d.Rakt.)

1754

The structure of the muscles[17] on the front of the neck is made to get the tongue bone all possibilities to work at its best.

There are muscle structures to lift the tongue bone and lift than also the trachea and closed the air pipe.

But most impressive is the amount of muscle that take care of the right position under the lower jaw and the symmetrical aspect of the movement of the tongue bone.

With this base the tongue can do more than only swallowing but has also an important task for closing and opening of the air pipe.

From anatomic view the assessment of mobility of the neck but also the muscles is very important.

There is literature about what will happen when muscle work too hard for more than 12 hours[18,19] but also what the reaction can be in the not-elastic elements of the muscle (cross links ) [20].

Both elements can caused an restriction in the movement of the cervical spine but also in the working of the muscle on the front of the neck.

Because an adaptation on an sustained contraction will occur but also an adaptation when an muscle is more than 12 hours in an elongation position and both elements will change the performance of the muscles that take care of the swallowing process.

What happen on sarcomeres level ?

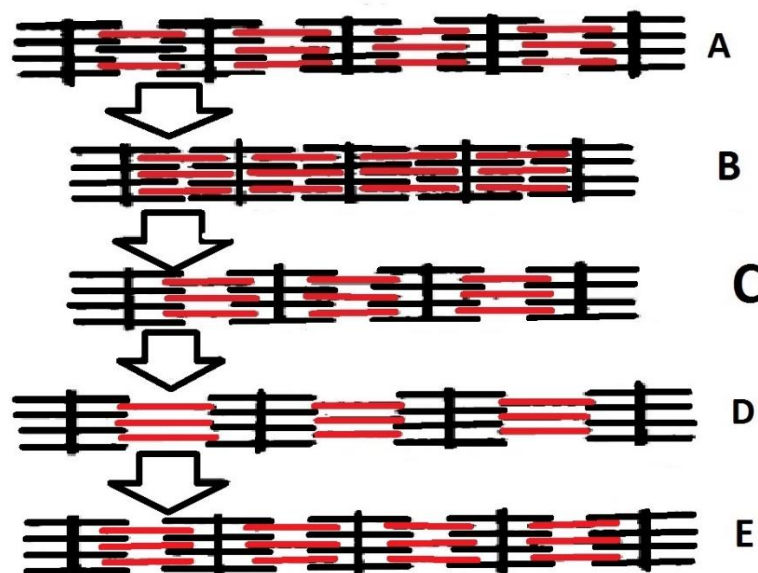


Figure 6



**Figure 6. Sarcomeres.**

A = normal situation.

B = High contraction that sustained for more than 12 hours ( there is only one investigation done with this duration, thus it can be possible that the reaction in the muscle will there, faster.

C= reaction of the muscle . Normal situation but one sarcomere is disappear and the stand is normal but the muscle is shorter

D = Elongation of the sarcomeres and when the reaction will be there certain after 12 hours is

E = one sarcomere in the muscle and the muscle stand normal and had the same length as in A, but is 25% weaker[21] !!

Test: Search the tongue bone of your one, take it between your fingers and hold it on that spot and swallowing . No move the tongue bone an little bit to the right and swallow now .

You feel the difference and feel how easy to move this tongue-bone is lateral, that is normal !!

Figure 6 published with the responsibility and permission of the author by j.v.d.Rakt.)

175!

The test , mentioned in figure 5 must be an referential point for the therapist to assess the mobility of the tongue bone in the lateral direction . That movement must occur smoothly and when we feel an restriction than we must search for the reason of that restriction.

**Investigation 2003 -2004**

In this period we examined every patient that was admitted in our Nursing home including the patient of the day-treatment. We had therefore all kinds of diagnosis but we were looking at mobility loss of the cervical spine and difficulty with eating /swallowing.

In that time we say 240 patients and from this group of patient were 100 patient that had very clear mobility lost in the cervical spine. Very clear mobility lost means that there is an restriction in the flexion ,extension , lateroflexion and rotation from more than 15 degree and certainly when there was an restriction in the lateroflexion/rotation on one side.

From this group of patient were 80 patient that had difficulty with eating! The compliances were very different from not like the eat because it was difficult to chew on it till patient that were not able to swallow on there on and this people had therapeutic training with the swallowing process[5]

That means, the group with restriction had 80% problems with eating and swallowing!!

**Table 2**

Diagnosis	Number of patient
Stroke	30
Parkinson	10
Dementia	20
Other neurological diseases	10
Orthopedically such as hip fractures	10
<b>Total</b>	<b>80</b>

All patient were examined by the speech therapist on the ability to feel and work with the food in the mouth and the stages of the swallowing- process and the physical therapist examined the mobility of the neck, tongue bon, muscle tone etc.

After the examination there was an discussion, which therapy must be perform the direct swallowing training or first an mobilization of the cervical spine or an treatment with both elements.



Was the speech therapist sure there was an damage of the swallowing center or damage that directly related was with the brain than there was always an swallowing therapy [5]

But also an treatment of the cervical spine;

Treatment consist :

- mobilization of the joint.
- slide technique of the nerves
- muscle tone decreasing therapy with increase of the mobility of the tongue bone.

After that was there an assessment with the occupational therapist to search for an reason that the restriction in the cervical spine occur. Looking for the attitude in the chair /wheelchair, bed etc.

1756

When the speech therapist has not the feeling that the damage wasn't directly in the swallowing center in the brain than they address to the physical therapist to start with the assessment and treatment.

The therapy by the 80 patient with swallowing problems was .

Table 2

	Stroke	Parkinson	Dementia	Neurological	Orthopedically
Active mobilization	24	4	10	5	7
Technique stimulation of swallowing [5]	2	2	4	1	2
Combination of both	4	4	6	5	1

Treatment period.

Table 3

	Stroke	Parkinson	Dementia	Neurological	Orthopedically
1 week	15	4	5	5	8
2 weeks	5	4	10	3	1
3 months	6	1	2	2	1
"always"	4*	1*	3*		

This are patient staying in an nursing home and the group \* " always" changes in that year . There were patient specially in the group Parkinson and dementia that had an further decline and had often an kombi – therapy to stay on an good level and of course wasn't that always possible and then is the swallowing process an very difficult and intensive treatment. But the best result were obtain with the kombi treatment. The combination of the swallowing technique [5] and the treatment to decrease the mobility restriction.

This investigation gives an clear answer that the conclusion of Prof. Bautmans investigation[4] was complete correct and that swallowing problems can be influence by "restriction" of the mobility of the cervical spine. Our investigation goes further to investigated:

1. What possibilities there were that caused that decrease of cervical mobility. Not only the muscle tone increase sec but also why this muscle tone increased. Par example an individual with dementia can have paratonia [26], but lying in bed this tone was moderate but sitting in an wheelchair this tone was severe.
2. Why that can have such an impact on the swallowing process [11,12].



In the group of individuals with an the stroke patient and in the Parkinson group, there were individuals that were not capable to hold the head in the middle.

They had always an latero rotation and that had an effect on the swallowing process. This head correction was possible[27] but never were this patient instead to hold that correction without an support. When the head correction was obtain and the head was support than was often the swallowing performance good but when the support was taken away or stay to long on his place, than the performance was less.

Another rear phenomena was, that the mobility of the tongue bone was decrease by an lot of neurological patient and then specially by stroke , Parkinson , dementia and the other neurological disease. When there was an side that makes more tone than the other there was an decrease in the possibility to move the tongue bone to the lateral.

This investigation makes us clear that we must refreshed our knowledge about the anatomic and functional performance of the cervical spine, the muscles on the front of the neck, the structure of the mouth but also about the function of the tongue to increase our capacity to treat this problem so long as possible .

**Muscle ( Figure 5)**

The conclusion must be that left and right must in balance to do the job swallowing and closing of the trachea good.

That there are an lot of solutions can be seen in the great number of muscle that has in small different procession in which an different stand of the mid part can be coped with. We know when this occur suddenly than the muscle has no answer, but when is goes slow than the muscle adapt. Thus there is an lot of possibilities and there is an adaptation in time.

Look to the muscle digastricus comes from the back of the jaw and goes to the retinaculum on the tongue bone and then to the front point of the jaw.

That means that this muscle trough the retinaculum makes an angle that we see nowhere in the whole body.

That muscle take care of the position of the tongue bone.

When we swallow we need the tongue to press against the front teeth to lift also the tongue bone and the complete trachea and by doing so the closing the nose and the trachea is easy for the uvula and epiglottis.

Without an tongue it is possible to learn it, but difficult ! That makes that the tong beside the transportation of the food in the mouth also has an function in lifting and closing of the trachea. Therefore it is very important to know what happen by changes of the muscles in the front of the neck and what when the posture and mobility of the neck is changes.

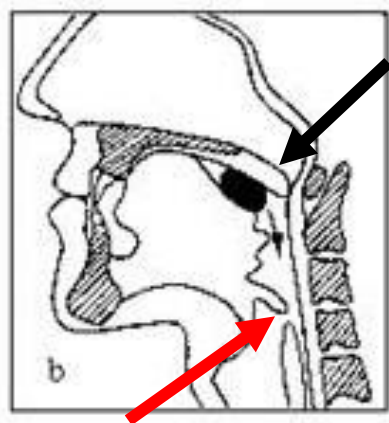


Figure 6

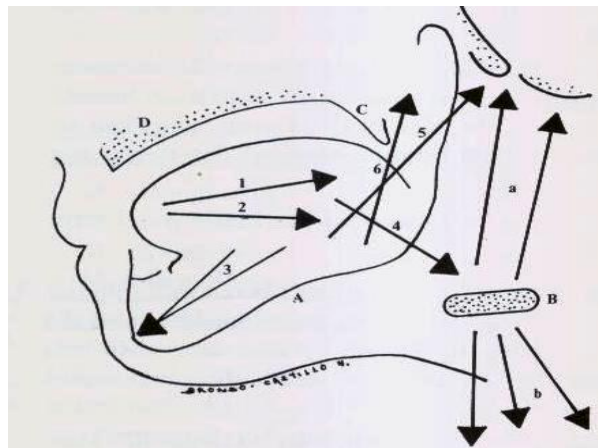


Figure 7



**Figure 6 Swallow.**

We see that the tongue push the food up in the mouth and push also the uvula ( black arrow) up , but on the same moment we see that epiglottis ( red arrow) now is going down to close the trachea.

**Figure 7**

The tongue and his possibilities to move and where lay is muscle anchor . The arrow 4 is the base of the tongue on the tongue bone. Arrow 5 and 6 the muscle anchor on skull/spine. Arrow 3 the anchor on the front of the lower jaw. Arrow a the muscle anchor of the tongue bone on the skull/spine. Arrow b the muscle to the ribcage/clavicula. Only 1 and 2 have no anchor that is the action of the point of tongue against the front teeth.

Figure 6 and 7 published with the responsibility and permission of the author by j.v.d.Rakt.

1758

We know that the tongue has an very important place in the whole swallowing process. Thus let do this .

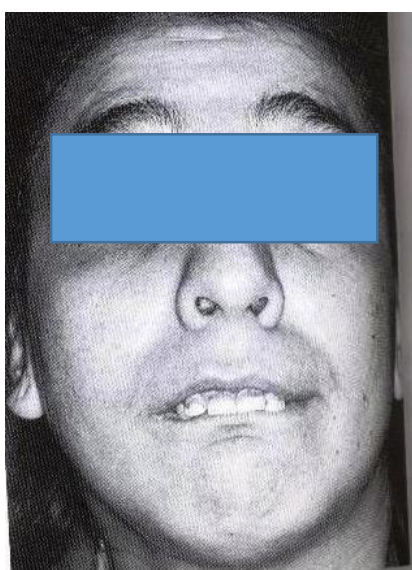
**SWALLOW !!** You will feel that ;

1. You shut your mouth and placed the jaw and teeth exactly on eachother.
2. The tongue push against the upper teeth .
3. The tongue goes up against hard palate
4. This movement goes like an rolling movement from the front to the back and on the evoke an swallow reaction.

Have you one moment think on closing the uvula ?

All this makes swallowing difficult and need more muscle force/coordination. This we willa ware when you push your tongue bone sideway. We have still an option to swallow but you feel that the muscle must work hard to correct that asymmetric.

That means that an alter position of the head, end-extension, end- flexion or an the antero-position ask for more muscle power/coordination to swallow and makes its hard and discomfort. Often you can heart the swallowing and when you look to the face than works all muscle of the face.



**Photo 8**

Patient with an brain damage.

When she is trying to swallow, there whole face is working to get the food away. Eating cost here very much energy and time and she must train to loss the extension power of the cervical spine and get an release of the muscle on the front of the neck because this muscles are now so elongated till the end and “no” movement is than possible anymore. The first problem is that mouth closure isn’t possible because the muscle on the front stand in an elongation. And there must be an extra force in that muscle to get the mouth closed and that increased the tone of the muscle on the front and make the swallowing more difficult. To decrease the tone see the next photo’s [5,25] .

Photo 9 published with the responsibility and permission of the author by j.v.d.Rakt.

**Photo 8**

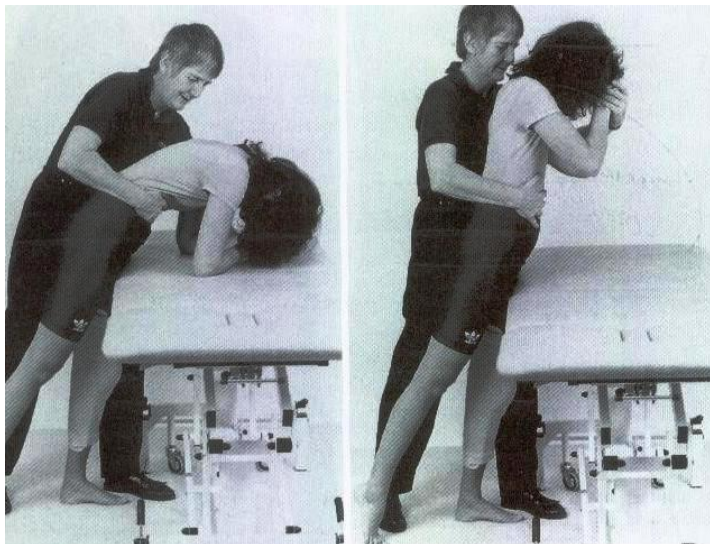


Photo 9

Photo 10

**Photo 9 and 10**


This is an part of the swallowing therapy ! The base of this approach is to create an good standing situation with enough support. The affected leg is splint , their stomach is standing against the couch and she is exercising in movement upper trunk forward and release the high tone in the spine. And make the movement back without an tone increase in the neck.

*Photo 9 and 10 published with the responsibility and permission of the author by j.v.d.Rakt.)*

This is an example what is possible by changing the tone in the whole body and which effect this can have on the swallowing performance. But this is an exercise to created more stability and less need of the high tone to control the attitude. But when she is place in an wheelchair or chair in which the stability is not present that she must create their “bad “attitude to remain sitting in that wheelchair /chair.

Therefore it is very important that the attitude is right and that isn't that this person must sit “straight “or “symmetrical” or “active “but important is that this person has the feeling that she is sitting stable and that the need for an high tone in the neck isn't necessary.

**Two examples.**



**Photo 11**

Individual after an stroke is sitting in an low wheelchair, with the first goal to give him the opportunity to go where want.....

But this wheelchair is on the back side lower than on the front. Therefore is the distance to the ground greater and must he correct his attitude by moving with lower trunk forward. His sit with an lower trunk [2] and that makes flexion of his legs difficult.

To get his wheelchair on the move, he used the extension and drive backward and only in difficult situation forward. To get this wheelchair to the front he fixated his right hand on the side support of the wheelchair.

*Photo 11* published with the responsibility and permission of the author by j.v.d.Rakt.)

**Photo 11.**

The form of the sitting of the wheelchair makes forward driving very difficult and to get this done he fixated his right hand on the side support and build an high tone on the not-affected to the back always to his head.

The tone on his affected side is less and this gives an restriction in his mobility of his neck. He complaint very often about the stiffness of his neck and that has also an reaction on his capacity to swallow and eat.

When this wheelchair has an better base of support without the angle back lower than on the front than the pelvis would have stabilized and he was capable to drive the wheelchair with less effort and had the tone increase of the upper trunk not necessary and his mobility of his neck would de normal.

His affected side has little tone and that is also in his affected side of the trunk .

That means that when he must do extreme action with his affected side no stabilization is there for that action through the affected side.

And the tone of the not-affected side isn't pathological but this side will pull more to the not-affected side because the affected side isn't capable to correct that.

That means that the trunk and also the head will go in an asymmetrical attitude and that has an reaction also on the front of the neck and the situation of the placing of the tongue bone.

His effort will give an negative effect on his performance to eat and swallowing.





**Photo 12**  
Individual with an severe hemiplegic paresis on the left side of her body. Here is also the pelvis rotated to the back but now is the sitting size to small and the angle between the sitting part and the rest to great. That means that she is continue “shifting” to the front. This is an “special” sit-cushion, still she must create too much of an extension in her upper trunk to hold here lower trunk in the wheelchair.  
This wheelchair has also the opportunity to “capsized” but that makes it for here very difficult to look around This through the angle between back-and sit-part.  
*Photo 12* published with the responsibility and permission of the author by j.v.d.Rakt.)

**Photo 12**

Again an wheelchair configuration that has no stable base [11,12] and asked from the individual more power to correct that problem.

The shifting to the front is brace by her by placing her hand between her legs and makes extension /adduction in the legs. That is an part of the back diagonal and increase the tone in here head and again more on the not-affected side than on the affected side.

This gives problems in the symmetrical but also to much neck extension and an stretch on the muscles on the front of the neck.

We see an increase of tension on the front of the neck , an mouth that isn't closed and an restriction of the neck mobility and that is the reason that her eating performance isn't optimal.

All activities that asked for more than normal neck extension and especially when this is asymmetrical , can give swallowing problems. Through the stretch the muscle on the front cannot do their job properly and when the tongue bone lies not symmetrical makes this swallowing painful and difficult.

The most important point are :

1. Extension of the cervical spine on the end gives an stretch on the muscle on the front often so much that patient search for an relieve by opening the mouth. Type A
2. Too much flexion of the neck press the front of the neck in each other and there is no room for the muscle to do their job. Type B.
3. Anterior -position gives an short cervical spine extension and therefore also an stretch on the front- muscle. Type C
4. The combination of an asymmetrical tone on the front of the neck and extension in the cervical spine gives often an painful experience when patient want to swallow.

All this situation has one common problem that the moment of action must be on time. React when the swallowing problems is there, is of course important but often is than the treatment very difficult.

The difference with the treatment investigated by individuals with osteoporosis [4] is that there problems lies in the joint and that manipulation give an increase of the mobility and an instant reaction of the muscle of the head and neck.

The loss of mobility makes the working of the muscles difficult but when the mobility was restored their function was also restored.

But when we have individuals with an neurological disease the tone of the muscles is changing and also the muscle itself can change [18,19,20] and then will the restriction have another reason.

When there are cross -links of changing of number of the amount of sarcomeres than the mobility restriction is very difficult to reversed.

An example when the anterior –position must be used by an individual over an too long period , what changes will than occur in the cervical and thoracic spine ![28]

1762

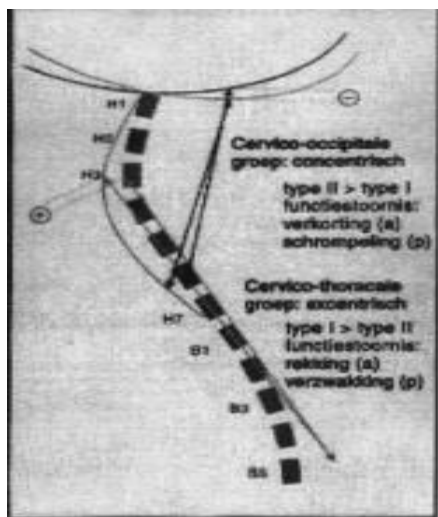


Figure 9

Figure 9.

What will happen when people are long in this position. The muscle will change not only in their length but also in the muscle type. Roughly we have fast muscle and slow muscle and the last one ( slow) are especially present in the long muscle of the spine. [29,30,31]

Older people will have less fast muscle fibers and more slow and this type will change when an attitude as the anterior –position is present over an long period. This makes figure 9 clear :

We see in the cervical spine the change of muscle fibers to the slow type with an shortening of the sarcomeres/crosslinks but the quality of the thoracic muscle fibers is also change and there is an increase of length of sarcomeres .

Figure 9 published with the responsibility and permission of the author by j.v.d.Rakt.)

### The muscle length change

In the thoracic spine the sarcomeres will elongated. That means that stretching of this part of the spine isn't possible anymore as before. An total extension of the thoracic spine will contributes for an upper trunk backward and will place the scapulae in the best position for movement of the shoulder to the back, but this extension thoracic will also take care for an optimal position of the cervical spine and placed the head in best position for eating and swallowing.

– In the cervical spine the muscle will reduce in length because there will be sarcomeres going out that means that the “long” attitude head position isn't possible anymore. This will push the vertebrae in each other therefore head-rotation and an contribution for the balance isn't possible. Further will this make an upper trunk movement forward more difficult, because this cervical extension is necessary to avoid an collapse to the front and makes on this level an upper trunk backward but with an thoracic kyphosis and both has an influence on the shoulder blades movement and on the mobility of the gleno-humeral joint and increase the danger of the impingement syndrome in the shoulder joint. Further one asked this for more effort and will create an higher tone.

– In the front of the neck will be stretch that will give problems with the swallowing performance but when the muscle adapt by recruited more sarcomeres, that means that the muscle will be elongated and loss an bit of the function. When this on one side more is than on the other than will swallowing be very difficult.

This will be seen by individuals with severe stroke and when this people are long sitting or lying in wrong attitude and we see this on the end of their live (Photo 7). And of course not all is to prevent but on right moment start with the treatment and make it also a ADL treatment, can



prevent of slowing down very much. The choice of the wheelchair is thus very important for this group of individuals and the greatest mistake is that the wheelchair is an chair for relaxation, no there must always an possibility and room for movement!

Because the lower trunk and the hip must take care for an optimal attitude of the head.

That means that the head can do his job, place the senses in an optimal position and make contact with the whole environment, with the minimum on effort and with an optimal head position also for eating etc.

Changes in the lower trunk have always reaction in the remaining part of the trunk. An lower trunk backward will push the thoracic spine in an flexion and the cervical spine must correct that in an extension . The diagonals will then be stretch on the back side and on the front the muscle will sink and on both side the possibilities of the muscle pattern will be reduced. The angle of the diagonal will increase and that means lesser contribution of the homolateral muscle structures and when the lumbar spine is in end- flexion no movement can occur in the spine as lateroflexion and rotation.

Balance in the sitting position to the side isn't possible from the lower trunk . That means that sitting for an long period cannot be changes by the patient on his on and we have an great problem.

### **Perception.**

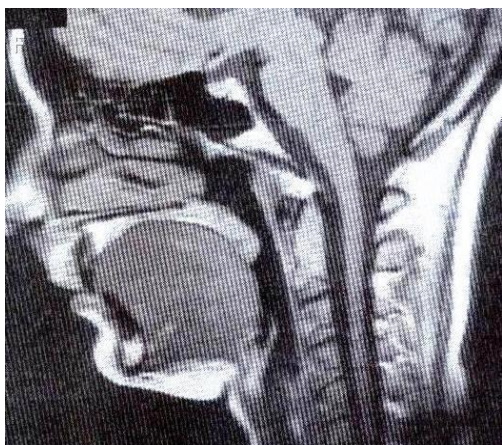
The perception of the face, the mouth, the tongue are very important for us to swallow perfectly and our tongue has an great perception. Everyone has experiences that when he is coming back of the dentist and he has drill an hole in your teeth how big that hole is, the perception of the tongue exaggerated but it is necessary to feel everything.

By stroke patient this perception can be affected even the taste can be affected but also the muscle spindles in the muscle of the mouth, tongue and front of the neck can be affected and that can lead to an swallowing procedure that isn't wright.

This ask for the treatment according the F.O.T.T –approach ( Facio Oralen Trakt Therapy ) [5] and often the speech therapist will do this, but all other therapist must participated to get the best results.

An tongues that has an low tone will have almost no perception, certainly when his is not moving , an tongue with an high tone has more perception but the perception is still severe damaged. When an tongue is, when the patient is awake, continue is moving between the lips has an very poor perception, but the connection with the brain is still possible. All this individuals ask for an special treatment and therefore it is very important that all therapist, nurses and care givers know what the must do to get the best situation for the patient to eat and swallow. When the mouth is standing open the tong is not capable to stand in “rest”- position but the top against the front teeth and part of the palate. This position is normal and on this way the tongue can give the brain continue information about his position etc.

By young children that position is first more extreme , the whole tongue stand against the palate.



**Photo 13**

**Photo 13 .**

The position of the tongue in rest by an young child. The tongue used the whole palate to give continue information to the brain.

The input beam that we – human – gives on our brain is probably on its highest in the tongue.

But also high and almost continue in the hands and the feet, that makes input so important because the feed and constituted the brain. The brain asked for an continue source of information where our hands/feet and tongue are.

*Photo 13 published with the responsibility and permission of the author by j.v.d.Rakt.)*

The stretch of the muscle on the front makes it impossible for the patient to hold this continue information position and the perception level of the tongue will thus decrease because the brain received to little or different input. When this brain is damaged, the brain will functioned on a lower level and the projection in the cortex will be lesser.

Often we see the tongue lies on the bottom of the lower jaw.

That can be caused by;

- An stretch on the front muscles.
- An low tone and therefore also an low perception
- An combination of this two

And then it isn't strange that this individual is scared when suddenly an spoon get in his mouth. We must realize that this tongue has some time need to restore the tone so far as possible and we must create an input moment extra to have more tone in the tongue thus we must work different by patient with the mouth open .

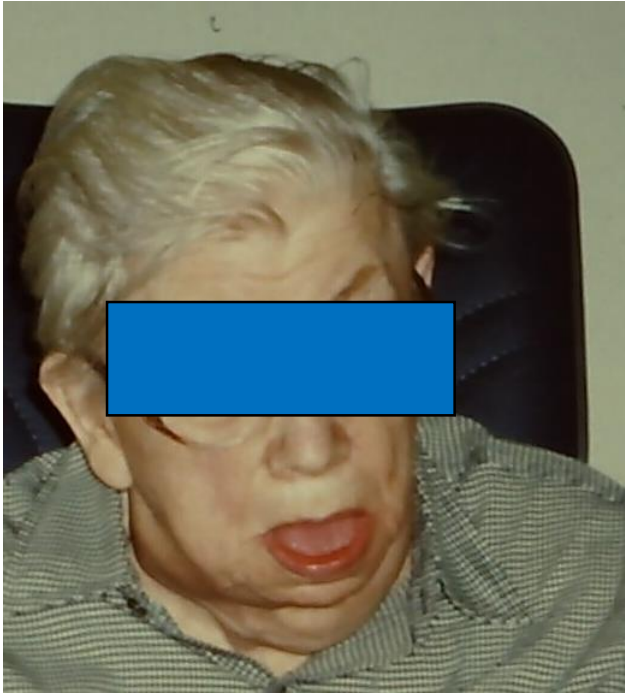

Photo 14.

This individual with Parkinson disease and an benign tumor in the front, has great problems to keep their head in the right position.

She is working even with their “eyebrow” to placed their head and eyes on the horizontal. Still the tone of the tongue is low and this position of sitting asked to much of her neck muscles and makes swallowing impossible. Further one push the benign tumor the tongue asymmetrical, therefore must her head be assist when she is eating with the speech therapist.

The therapist will start with an stimulation of the tongue to increase the tone and start than with eating.

*Photo 14* published with the responsibility and permission of the author by j.v.d.Rakt.)

**Photo 14**

**Treatment patient with the mouth open and with tongue at the bottom of the under jaw.**

1.The attitude try always an sitting attitude when this people go to eat. When an chair/wheelchair isn't possible, create an attitude in bed in which the patient sit with an “long” neck.

When an chair or wheelchair is possible tried to create an attitude that start with an lumbar spine in extension by rotating the pelvis to the front. Than the thoracic spine will better stretch and created together an “Long” neck in the cervical spine. By an stroke patient pay attention that the patient has enough support on the side. Because when he must work in bed to hold his stability than will the tone be asymmetrical and that can influenced the tone on the front of neck and give the tongue an wrong position. Both positions in bed or in the (wheel)-chair, be sure that the individual must not work to hold his head in the right position because that is often an extension with will influence the muscle on the front of the neck . Give than assistance see photo 15.

2. Always be sure that the mobility of the neck is good and when that is not the case than must an physical therapist this do short for this individual goes to eat. There were individuals that came out the bed for eating, but transfer was so heavy for this patient that he block his neck. This transfer was after that realized with an passive lift. The lady on photo 14 has too much effort in the chair to hold their head in the right position and therefore the eating was starting in bed see figure 1.

You have that two option:

A. Eating in bed

B. Or realized after the transfer an relaxation. – Real mobilization is than often not the good treatment [7] because the tone will have create this mobility loss. But this tone can also take care of an joint displacement and then is that treatment very important.

But the F.O.T.T. approach [5.33] or the treatment Die Orofacilae Regulationstherapie[32] is than important to get the best position, tone and perception to make the swallowing possible and thus working toward “normal” eating .




**Picture 1.**

Bending the knee will prevent too much tension [23,24] on the nerves of the leg. So will he be able to rotated his pelvis to the front. That is the base for support thoracic spine and the best head position Try to fixated from lumbar and cervical so free as possible.

*Picture 1.* published with the responsibility and permission of the author by j.v.d.Rakt.

1766



**Figure 1**



1767

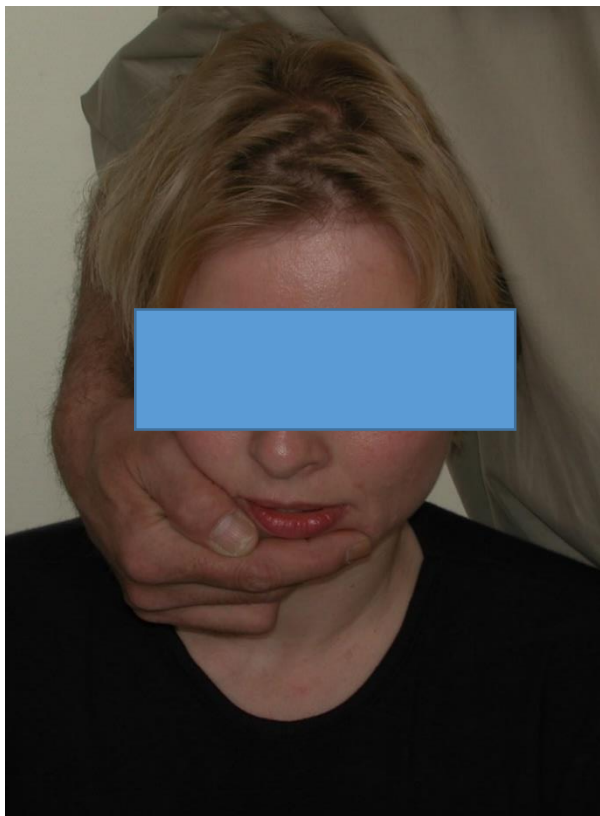

Photo 15

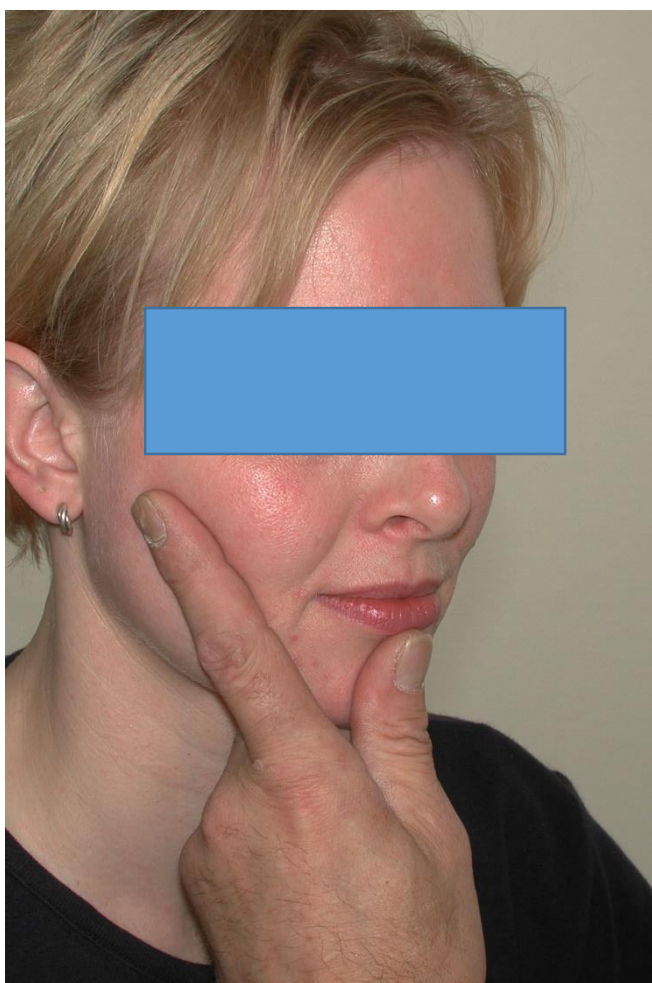**Photo 15**

Facilitation technique with much support of the head.

**F.O.T.T.** [5, 32.33.34] The therapist must choose which side he want to support. When he support on the affected side, he cannot with this hand facilitated , he must do that with the other and someone else must give the person the food. Stand he on the not-affected side that he can with his hand and breast hold an “long” neck , with is thumb the cheek. With his first finger under the under lip for the jaw opening /-closure and the second finger can feel and stimulated the movement of the tongue bone. This technique will release some tension of the neck to hold the correct position .

Great disadvantage of this technique you stand and you stand beside the patient and see not everything and this is very difficult.

*Photo 15* published with the responsibility and permission of the author by j.v.d.Rakt.)

**Photo 16****Photo 16 F.O.T.T.**

Facilitation and sitting in front of the person.

The first finger on the cheek to prevent that there stay food in the cheek on the affected side.

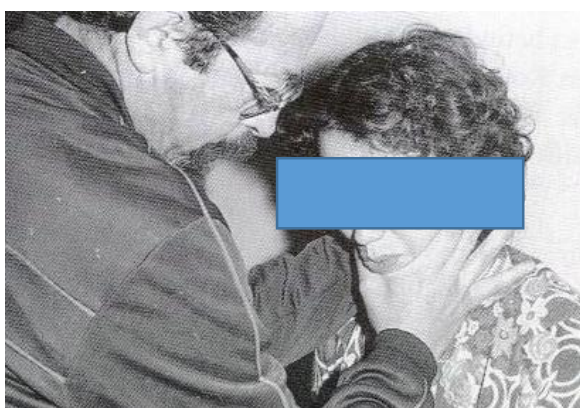The thumb makes the opening and closure of the jaw and lips better.

With the bended second finger under the jaw and the other two fingers can control and stimulated the movement of the tongue bone. Difficult now is to hold the "long" neck position and symmetrical head attitude.

But now we can sit in front of the patient and observe better and by sitting the head movement is also better than in that standing position because everyone has than the tendency to look up.

This technique is also teaching on the nurse staff on the ward to get the optimal eating and swallowing situation.

*Photo 16* published with the responsibility and permission of the author by j.v.d.Rakt.

**Photo 17****Photo 17.**

In the Orofacial Regulations therapie [32] was this one the most use technique sitting in front of the person and with two hand now was also the possibility there to control the head.

But another will give the food and stay an therapy situation .

Especially the control about the under jaw is great.

*Photo 17* published with the responsibility and permission of the author by j.v.d.Rakt.

**Nerves influence on the swallowing performance.**

Not the joint less- mobility, but the increase tone on the back of the neck has the greatest influence on the swallowing performance by an lot of person with swallowing performance in long care facilities. See table 1.

That means that often this people are sitting in wheelchair that support the whol body but often with an rotation of the pelvis to the back.






That will asked for an compensation to hold the thoracic collapse under control and that will be done with an forcing extension in the cervical muscle and that muscle can have an pathological tone that increase this .

But also pain will increase the pain and one of this “pain” situations can be created through an stretch on the nerve system [23.24]

An example:

1769



**Photo 18** ( published with the responsibility and permission of the author by j.v.d.Rakt.)

This photo is taken in an nursing home of an individual with an vascular dementia. The stroke symptoms are not very clear because on both side of her body is tone increased. All neurological diseases, therefore also all different forms of dementia have an increasing of tone but often on different stages in the disease[35]. This means that the selectivity of the movement will decrease when this disease will go further and that has an very dominant effect.



When the tone increased and the selectivity is decreasing than the possibilities to changes attitude or make movements also decreasing and that means that people are not capable to change and will have more problems.

When we are growing old, there is also an loosing of power but often the selectivity stay on an very high level and that gives us the possibility to change the movement, attitude etc.. We can adapt !!

Looking to the photo 18 we see;

1. An woman that is sitting in an wheelchair that is built to make every movement impossible.

There is no movement possible outside the wheelchair because the transfers must occur with the elevator. We see that the sling of elevator is still in the wheelchair. It is always wrong to let this sling in the wheelchair because;

A. It can have influence on the sitting part of the wheelchair.

B. This sling can give deformation of the skin or even more in the muscle and will be stimulated in the creation of pain and pressure scores.

C. We don't know when this lady is tired. Because when we must bring this sling under this individual we noticed that here body is very stiff and that this is very difficult to do and that means that this lady has sit to long and that we have ask far too much from here and that will influence the quality of live.

2. The leg -rest of the wheelchair are standing up and that give an extension in both legs but also an lower trunk backward and that will give an rotation of the pelvis to the back. This stand of the pelvis will lower the tone of the buttock muscle and will sitting and correction of the sitting position very difficult and also with more pain.

Bent Engstrom[11,12,13] has investigated, what the reaction is of an body that is forced in a lower trunk backward-position and say an thoracic collapse to the front and that asked for an cervical action to the back – the antero position of the head.

That thoracic collapse isn't there on photo 18 but the cervical action far more. She makes an total upper trunk backward because the shoulder are both in retraction and that we see on the poor action and forward movement of the arms. She can touch the table right side less than left, but that is for both the endpoint of the movement and there head is backward with an high tone in the neck.

3.This will have an restriction on the muscle on the front of the neck and therefore also on the possibilities of the eating and swallowing. She must work hard to chew and swallowing the food. "The food is given on an too high level": was one answer in an course, but that isn't true because she wasn't capable to lower here head and release the tension of the muscles on the back of the neck.

Her swallowing and her sitting is decreased by the lower trunk position. But that trunk position is only possibility for her to adapt on the increasing of the nerve tension.

This tension on the nerve system that the nerve -system must translate through an upper trunk backward. That is the reason that the thoracic collapse isn't visible.

She has therefore not only pain by an lower tone in buttock and no possibilities to change this position but also is there an defense muscular through the high tension on the nerve system that make it for her impossible to lower the tone of the upper trunk and that will influence the possibilities of eating and swallowing.

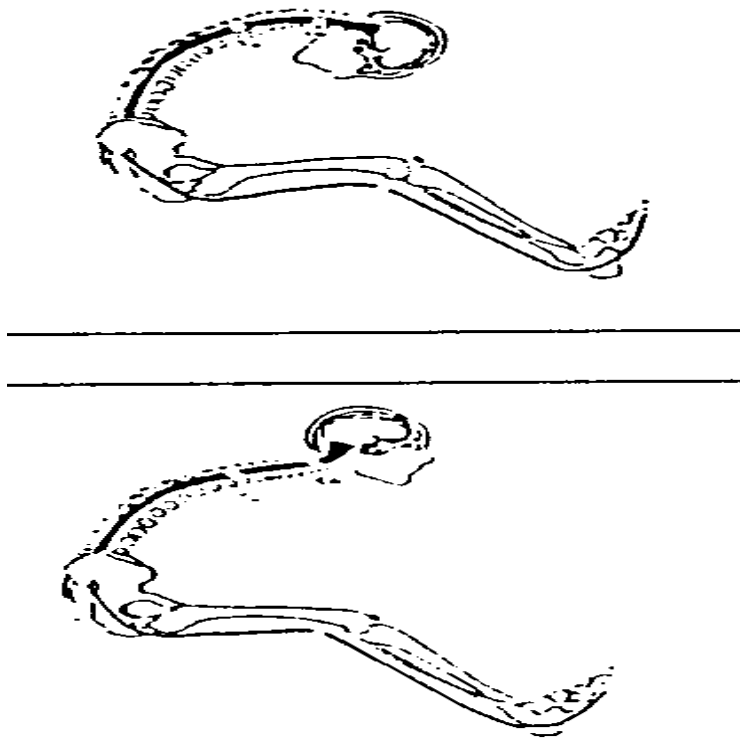
This will destroy her quality of live !

This "mistake" with the legs-rest of wheelchair is very often the reason that especially individuals with neurological disease but we see this also by individuals with an amputee that sitting in a wheelchair is advised to hold the affected leg so high as possible and we created an obstruction in the possibilities of sitting , moving etc.

The nerve system mobility is an total one:



1771

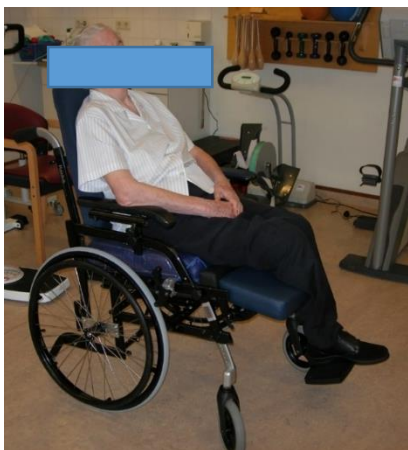

**Figure 8.**  
The “slump” technique.[24,25]  
The tension and the elongation of the nerve system /tissues is in the upper drawing on his end. That means that the leg are in extension, the pelvis is rotated to the back with an lumbar kyphosis and the whole thoracic is in flexion.  
The last part is cervical flexion to make this tension and elongation of the nerve system complete.  
The drawing under give the possibility that the individual makes to get less tension on this system through making an neck extension. *Figure 8* published with the responsibility and permission of the author by j.v.d.Rakt.

**Figure 8.**

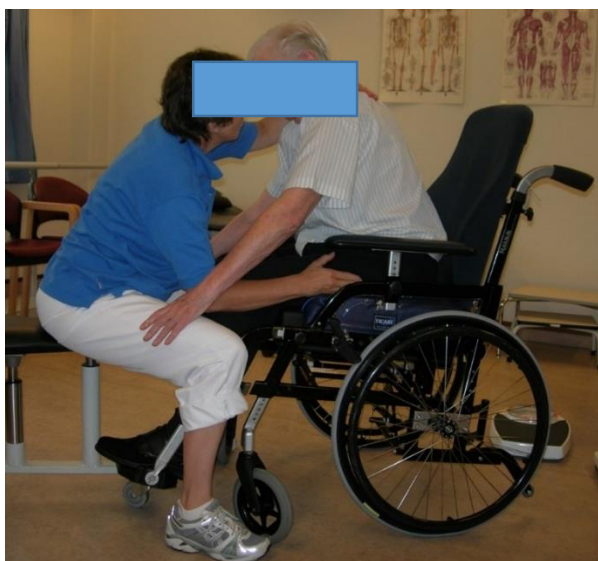The adaptation that the lady on photo 18 makes is the only way to get the stretch of the nerve system. The person that assist her with eating adapt her attitude on the attitude of the lady. Perfect example of the action of the mirror neuron of the brain[36].

Especially by older people will this occur sooner and when this individual has an neurological disease than will this have an greater impact because the selectivity is less and the individual has less possibilities to create an good solution.



**Photo 19**

**Photo 19**  
An attitude in an wheelchair with too much neck extension.  
Sitting in an wheelchair and especially the whole day ask for possibilities to change the attitude so often as possible.  
And very important is the possibility to get out the wheelchair and stand up and then it is important that there is an good “Vorlage “.  
On this photo this individual has too much attitude in the upper trunk backward. This ask more muscle activity than normal.  
This must have an reason !!  
Still on this photo you may say that this her attitude also because of the backrest but what happen as she move forward.  
*Photo 19* published with the responsibility and permission of the author by j.v.d.Rakt.)



**Photo 20**

**Photo 20.**

On this photo the therapist is starting with an "Vorlage" exercise but she feels the resistance that starts in the upper trunk and makes it impossible for the individual to get enough movement to the front.

One leg (Left) stands on the foot rest but that rest stands down; this cannot be the restriction.

But the other leg is amputee under the knee and that leg is in extension and after the operation the nerve is also hurt and an elongation isn't often less possible. Look at her head, still the same attitude as on photo 19.

Photo 20 published with the responsibility and permission of the author by j.v.d.Rakt.).

The care for the leg that is amputee, is often to place this leg in extension to avoid contractures but we create so contractures[37]!!

The tension in the nerve-system and nerve-tissues when this leg is rest on the special leg-rest, is high and that will lead to an higher muscle tension ( Defense Muscular) .

This muscle tension isn't the tension we see by neurological disease ( spasm, rigid or paratonia) but will lead to an decrease of knee extension and loss of muscle power in the extensors of the knee.

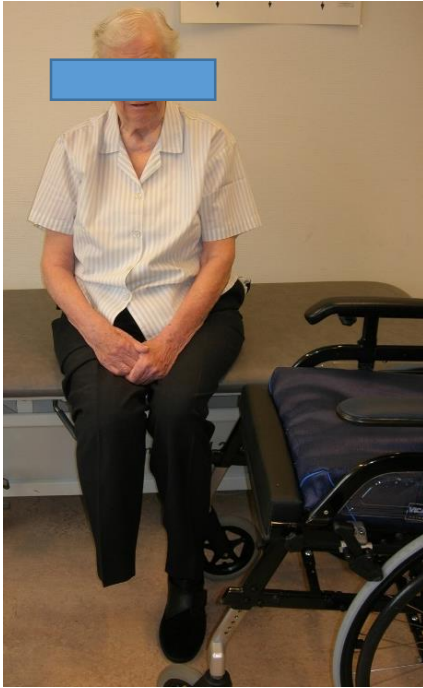This high tension will be give an change of the proper position of the knee. Often the high tone of the hamstrings restrict the normal translation of the tibia to the front and that can give complaints of the knee joint and more tension in the muscle that flex the knee[38].

Then the problems ( contractures) can develop because the tension is so long present that the sarcomeres length can changes.

When there is also an neurological disease than will this reaction be much bigger and faster and also the adaptation of the remaining part of the body always to the head and has therefore an direct effect on the head position and on the capacity for normal eating and swallowing.

We create problems in the knee when we place this tension on the nerve system and create the "contractures" were we are so afraid.

That this is an neural problem is clear to see on the next photo's 21 and 22.

**Photo 21**

Sitting on an bench there is no tension in the nerve system and the upper trunk isn't any more in an position upper trunk backward but more relaxed.

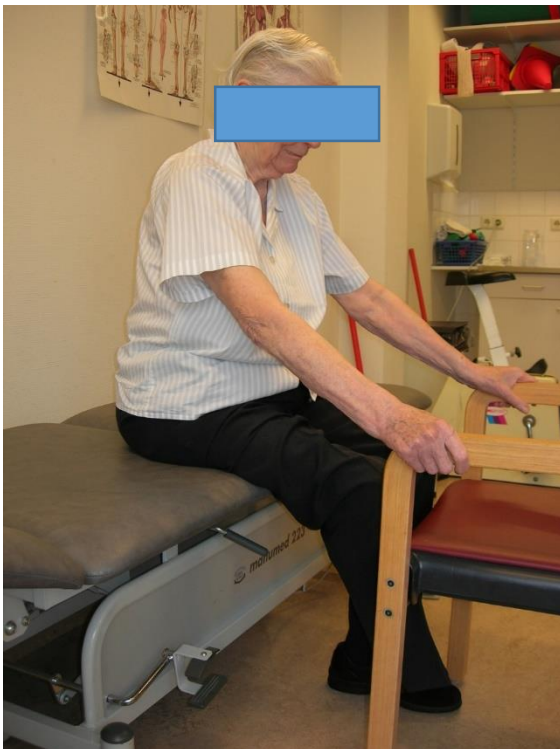The right leg is in the knee in flexion and that makes an attitude to avoid the tension not necessary !

In the wheelchair we see now that there is an pillow placed to give an lower pressure on the buttock and therefore give more comfort for the sitting times.

This is often also done to avoid pressure scores but that is an misunderstanding. Low pressure [39] and long-time will lead also to the creation of pressure scores because the pain isn't feel any more. Furthermore will this give an pelvis shift backward and that will lead to an lower tone in the buttock muscle and will have an negative effect on the possibilities of changing the attitude and standing up , stand and walk.

Even the expression on her face is more relaxed !!

*Photo 21* published with the responsibility and permission of the author by j.v.d.Rakt.

**Photo 21****Photo 22.**

In this position is making of an movement to the front starting in the upper trunk no problem.

On photo 20 we see the head reaction to the back, now is this no problem and is she capable to standing up with an good "vorlage".

With the chair turned around and then support on the side rest of the chair will this standing up with one leg be possible and can she stand and with support on the chair turn.

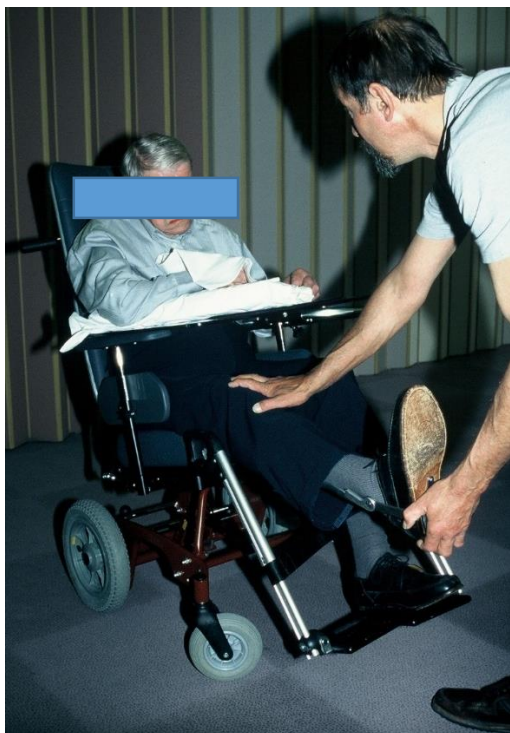The "vorlage" starting from the upper trunk makes it possible to get the most weight in front of the feet and makes it easy to get in balance with support to the front.

This balance performance on this way makes often "pivot" ( From heel to forefoot) possible.

*Photo 22* published with the responsibility and permission of the author by j.v.d.Rakt.

**Photo 22**

Tension on the nerve is especially when the tone is low in the affected side an reason that sitting in the wheelchair is very difficult and even painful

**Photo 23.**

This individual with a paretic side on the right side has a low tone in the affected side and his condition is decreasing.

When he sits in this wheelchair he often falls asleep and then bends his head and upper trunk.

The leg rest cannot go further up, still he sometimes will be awake through violent movements of his affected shoulder.

Sometimes people think of an epileptic insult but when the affected leg is lifted in extension his shoulder will react with elevations that are violent. That means that when he bends his head and upper trunk.

He places tension on his nerve system !! Stretching his paretic leg gives that tension increase in his right shoulder through the increase in tension of the nerve system.

Photo 23 published with the responsibility and permission of the author by j.v.d.Rakt.

**Photo 23****New techniques.**

From other diseases with swallowing problems, new techniques have developed that can stimulate the muscles of the front side of the neck and help the individual with swallowing.

This will have the most result when the muscle coordination and power is too less to swallow and that it therefore is an indication for individual with a stroke.

But still, there must be awareness what the neck position/tone is because otherwise the stimulation on the front will inhibit a good treatment.

The first one is electric stimulation of the muscles

The other one is stimulating the individual to use the muscle on a proper way and that is more an education technique for an progression of the coordination.

**1. Electric stimulation .**

The purpose of this apparatus is to help the individual with the swallowing movement. That means that the first important part is :

That the attitude is correct and that the muscle on the front of the neck stands correct. To get a correct swallowing movement it is still important that the tip of the tongue has a fast point against this tip of the upper teeth and this apparatus will help by activation of other muscles in the front of the neck, to lift the tongue bone and make the swallowing movement complete.

This means that there is no stretch on the muscle on the front and that the neck has the right position ( "long neck " ) and that the tip of the tongue has the possibility to fixate against the upper teeth.. Now will the apparatus give a stronger contraction that makes the swallowing better possible and will increase the power and the coordination of the swallowing process.



1775

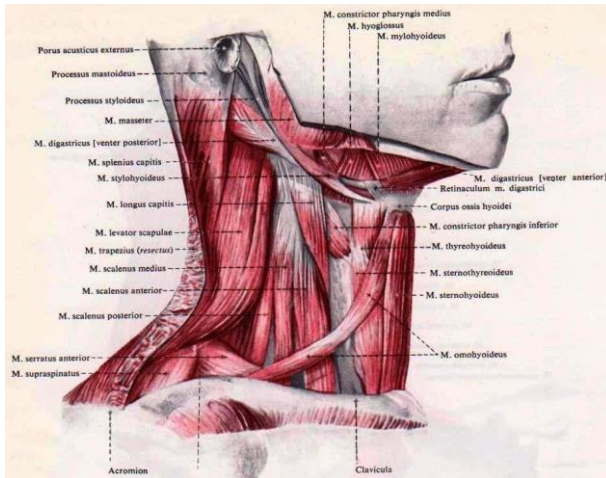


Figure 9

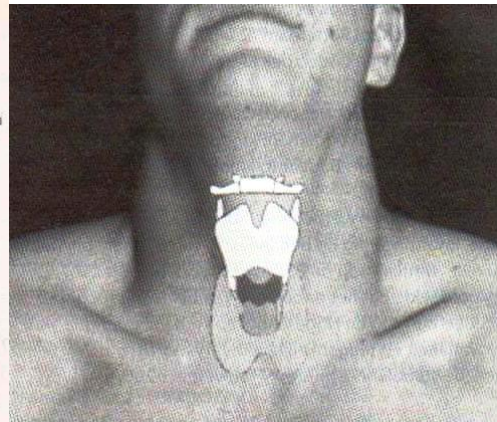


Photo 23

**Figure 9 and Photo 23.**

Figure 9 show all the muscles that there are around the neck, but pay special interest on the muscle that goes front the tongue bone up and down. Look also to the great differences in muscle pattern and that gives an clear picture that this must be an area in which the cooperation and the coordination must be very good to get the best result.

Photo 23.

Let us see where this tongue bone lies in the front of the neck and it has an cartilage connection with the upper part of the air tube.

Figure 9 and photo 23 published with the responsibility and permission of the author by j.v.d.Rakt.

With this apparatus we can train the muscle of the front of the neck to give the support that is necessary to lift the tongue bone. Than will there be an closure of the noise part and the air tube and is the way to the stomach optimal, first practise by individuals with M.S. [40].

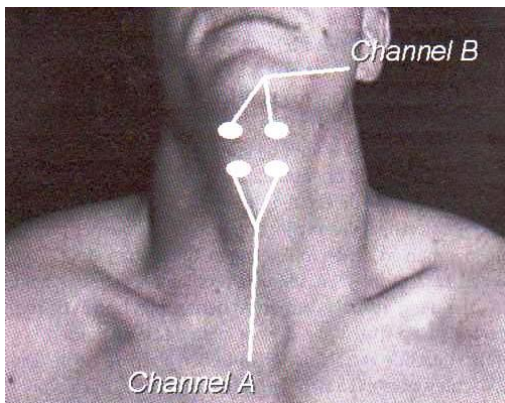


Photo 24



Photo 25



**Photo 24 and Photo 25.**

Give the position of the electrodes. We see two group ( Channel B and Channel A ) that is placed both above the tongue bone.

Channel B will activated the muscle in the mouth bottom and that give the tongue bone an forward stimulus.

Channel A will lift the tongue up.

Photo 45 gives an impression of the apparatus.

Photo 24 and 25 published with the responsibility and permission of the author by j.v.d.Rakt.

1776

**2. Myofeedback.**

Another approach is the myofeedback[42,43], that is not an stimulation of the muscle by give electrotherapy that will give an muscular reaction but this is more an learning system that show the individual with an swallowing problem what he do when he try to swallowing.

That means that there must be some muscle activity and some coordination present because otherwise it is impossible to show the individual what he try to do in activation of the swallowing process.

Of course is an combination of electro stimulation and myofeedback an perfect combination.

The attitude must be correct and the muscle on the front of the neck must be in the right position.

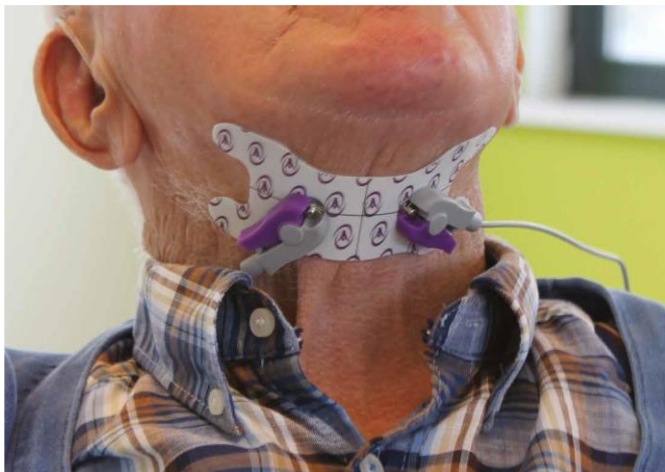

Photo 26

**Photo 26.**

Placing of the electrodes and this almost the same as by the electro stimulation . Again on the mouth bottom muscles ( with m.digastricus , this is for the forward movement of the tongue bone . The other electrode stand on the muscle that must lift the tongue.

Photo 26 published with the responsibility and permission of the author by j.v.d.Rakt.

This is the start movement and the individual see that approach on the screen and is stimulated to get the jump of the “kangaroo” higher but also further to the front.



**Photo 27**

This what the person see. The kangaroo makes an jump and he decided how high and how far this jump is.

Of course is this an simple ( too simple explanation) but the important part is that the person cvan see what is effort do.

Photo 27 published with the responsibility and permission of the author by j.v.d.Rakt.)





**Photo 27**

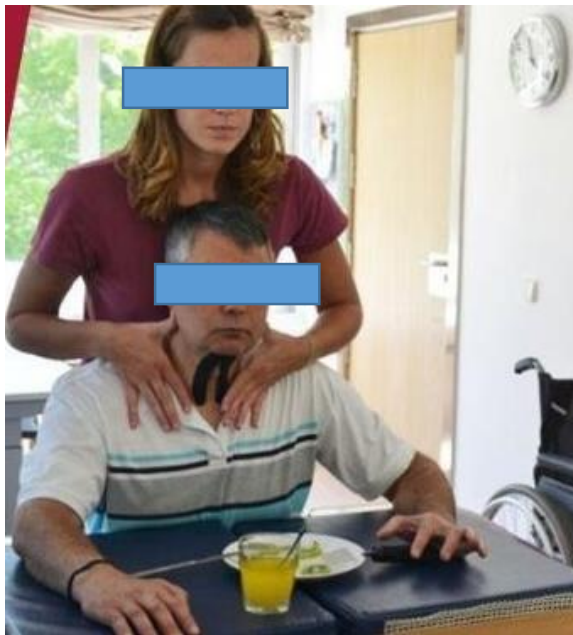**But :**

Again all start with an good attitude, because the tone of the front of the neck must almost be normal. Also movement to the side must be possible passive ( assessment) with no resistance because that will make it difficult for the tongue to move in the mouth on an normal way . This we can test by taking the tongue bone and move it sideways.

That movement must be done with an higher speed than we normally use by the MAS –test [44] or Mas-P[45] because we want to know of the tone is normal. Spasm in the front of the neck is speed dependent thus therefore we must test with an certain speed.

When we feel that this increase the tone than it is important to inhibit the tone on the front of the neck before we start with the treatment .

1777



**Photo 28.**

There all kind of possibilities to hold the tone on an normal level or on an level that look as almost normal.

Here we see the placement of kinesiotope[46] starting from the bottom of the under jaw and is placed especially on the muscle that play an part in the up and front movement of the tongue bone muscle .

This can also be indicated when there is an slight sideways movement that is very difficult to control.

Kinesiotope has certain rules what is stimulating and what is inhibiting and that make an great difference when this isn't done right.

*Photo 28 published with the responsibility and permission of the author by j.v.d.Rakt.)*

**Photo 28**

An combination of all measures is very important when the center in the brain responsible for the swallowing performance are damaged.

This isn't an task only for the speech therapist or the occupational therapist or the physical therapist , this is multidisciplinary task in which the nurse on the ward is also very important because they will do the most eating task. Starting with the sitting attitude must also be assessed of the movement that this individual can make are coming from the lower trunk.

The individual on photo 28 sit on an normal chair with the lower trunk to the front , that means that his legs are in flexion mostly under the chair. Now he will support his trunk on his elbow on the table. That will give an decrease of the movement of the trunk to back therefore also an increase of the activity of the front diagonals and the shoulder will go in protraction. An individual with an stroke that has an strong tone on the affected side in the upper trunk ( back diagonal) will have problems to hold the elbow on the table and will not able to get support on it.

That means that the tone in the back of the neck is high and that the head is rotated to the back on the affected side and that will created an stretch on the muscle on the affected side on the front of the neck. Even on photo 28 is an reaction visible that is evoked by the therapist when is



try to decrease the tone of the muscle. The left hand is reacting with an lift of the hand /fingers of the table and movement in the shoulder to more abduction and that means that the flexion movement synergy is active and that the elbow is slip from the table. That means that the support on the affected side isn't there and that evokes an reaction in the head and neck.

The therapist stand behind the individual and try to inhibit the movement of the head to the back, this to prevent that the back diagonals are active and that the neck lordosis increase because than the stretch on the front is greater. Swallowing therapy is by individuals with an damage of that part of the brain very difficult and must be done by all members of the team .

And mistakes are quick done especially when there is almost no problem with the swallowing process.

1778

Photo 19: Members of the team has noticed that this individual with dementia isn't eat so well as several months therefore. She was healthy but she had get an new wheel chair and she was very glad with this chair but after several months the eating was difficult. She has difficulty with the chewing and the swallowing. Members of the ward had proposed to give there other food on which the chewing wasn't necessary but other members give an sign that chewing is an brain activation that is very important in the inhibition of the dementia process.

There was in the multidisciplinary team an question that was spoken in the team and together they say the solution that the wheelchair with the leg-rest up makes it for this person difficult to eat well.

Swallowing is very difficult and ask of all our team members daily good observation and consulting.

Ita. J. Sports Reh. Po.

Italian Journal of  
Sports Rehabilitation and Posturology

Ita. J. Sports Reh. Po.  
Italian Journal of  
Sports Rehabilitation and Posturology



## REFERENCE

1. J. van de Rakt, S. McCarthy-Grunwald. *Diagonals part 1* .Ita.J.Sport Reh. Po. 2015. 2; 3; 146 -169
2. J. van de Rakt, S. McCarthy-Grunwald. *Diagonals part 2 – Assessment and Trunk Rules*. Ita.J.Sports Reh. Po. . 2015 ; 2; 2 ; 260 -298
3. Barnes M , Johnson G. *Upper motor neurone syndrome and spasticity*. Cambrigde University Press 2001. Page: 12-78
4. I. Bautmans, J. Demarteau, B. Cruts, J. Lemper, T. Mets. *Dysphagia in elderly nursing home residents with severe cognitive impairment can be attenuated by cervical spine mobilisation*. Journal of Rehabilitation Medicine, 2008, Oct;40(9):755-60.
5. B.Lipp. W. Schaegel. *Wege von anfang an* . Neckar- Verlag. 1996. ; 125-167
6. J. Van de Rakt. *Het zou verboden moeten worden*. Tijdschrift voor verpleegkundigen, 2005 12.
7. Mulligan B. *Manual Therapy*. Hutcheson Bowman & Stewart 1995 .Pag;35-44 ISBN 047303039X
8. J. van de Rakt. S. McCarthy-Grunwald. *Possible treatment for the Pisa - Syndrome by Parkinson disease. An case report*. Ita. J. Sports Reh. Po.; 2020. ; 7 ; 2 ; 1522 -1545
9. B. van Deun, N. van den Noortgate, C. Saucedo, A. van Bladel, D. Cambier. *Paratonia in Flemish Nursing Homes: Current State of Practice*. American Journal of Alzheimer’s Disease & Other Dementias. 2018. 33(4). p.205-214
10. J. van de Rakt. S. McCarthy-Grunwald. *Treatment possibilities of “contractures” by neurological diseases*. Ita. J. Sports Reh. Po.; 2020: 7 : 1 ; 1450-1478.
11. Engstrom B. *Ergonomie sitzen im rollstuhl*. Posturalis Books 2001.; 95-172
12. Engstrom B. *Ergomic seating an true challenge*. Posturalis Books.2002. ; 173-211
13. J. van de Rakt. *Zitten, waarin ?* Tijdschrift voor Ergotherapie, 1993 3, juni 3. 21-9,
14. Kaltenborn K. *Manuelle therapie der extremitatengelenke*. Olaf Norlis Bokhandel.1977 : 67-87
15. Warmerdam A. *Manual Therapy*. Pine publications 2002 : 145-209
16. J. van de Rakt, S. McCarthy-Grunwald. *Diagonals Part six. Standing up and the static reaction*. Ita.J.Sports Reh. Po .2018. 5 ; 2 ; 926 – 989
17. Spalteholz R. *Handatlas der anatomie des mensches*. BSL 1971. Pag: 288-355. ISBN 9060606159.
18. G. Goldspink, C. Tabary, JC. Tabary , C. Tardieu, G. Tardieu. *Effect of denervation on the adaptation of sarcomere number and muscle extensibility to the functional length of the muscle* , J. Physiol. J Physiol. 1974 Feb; 236(3): 733–742.
19. J. Kool. *Seriengipse zur kontrakturbehandlung in der neurologische rehabilitation*. Kool,J. Der . Physiotherapeut (1992) 2 14-21.



20. J. Haus , J. Carrithers, S. Trappe and T. Trappe. Collagen, cross-linking, and advanced glycation end products in aging human skeletal muscle. *J Appl Physiol* (1985). 2007 Dec;103(6):2068-76.
21. W. Vattanslip, N. O'Dwyer, and J. Crosbie, J. 'Does spasticity contribute to walking dysfunction after stroke?' *Journal of Neurology* 1998. 1998 May; 64(5): 628–635.
23. Butler D.S. *The sensitive nervous system*. Noigroup Publication. 2000 ; 276-340 .
24. M.Shacklock. *Clinical Neurodynamics*. Elsevier, Butterwoth, Heinemann 2005 : 160- 174 . ISBN 0750654562.
25. Davies P. *Starting Again*. Springer Verlag 1994 :181-215. ISBN 3540559345
26. J. Hobbelen . *Paratonia enlightened. Defenition, diagnosis, course, riskfactors, and treatment*. Thesis. Enschede, Gildeprintdrukkerijen, 2010.
27. J. Van de Rakt. S. McCarthy-Grunwald. *Possible treatment for the Pisa - Syndrome by Parkinson disease. An case report*. *Ita. J. Sports Reh. Po.*; 2020. ; 7 ; 2 ; 1522 -1545
28. Galender D. *Eatings Handicaps*. Chales C. Thoms Publisner Illinois 1979. Pag: 237-267. ISBN 039803771X
29. Lieber R. *Skeletal muscle, structure,function &plasticity*. Lippincott Williams& Wilkins 2002 : 224- 286. ISBN 0781730619
- 30 Hettinger T. *Isometrisches Muskeltraining*. George Thieme verlag Suttgart 1983 ;82-119. ISBN 3133495054
31. Basmajian J. *Muscles Alive* . Williams & Wilkins Baltimore 1978 : 379-400. ISBN 0693004131
32. Morales R. *Die orofaziale Regulationstherapie*. Pflaum 1998 : 130-146. ISBN 3790507784
- 33.Kalf H. Rood B. Dicke H. Van Keeken P. *Slikstoornissen bij volwassenen* .BSL 2008 :73-93ISBN 9789031350605
- 33.Nusser- Muller- Busch R. *Die theraie des Facio –Oralen trakts* .Springer Verlag 2007. 178-186. ISBN 9783540496830
- 34.Schalch F. *Schluckstorungen und facilais lahmung* . Gustav Fischer Verlag .1984 : 37-41. ISBN 3437109859X
35. B. Van Deun. *Paratonia , Assessment, associated motor decline and interventional strategies*. Thesis Gent Uni 2018.
36. S. Acharya and S. Shukla. *Mirror neurons: Enigma of the metaphysical modular brain*. *J Nat Sci Biol Med* 2012 Jul;3(2):118-24.
37. J. Van de Rakt. S. McCarthy-Grunwald. *Treatment possibilities of “contractures” by neurological diseases*. *Ita. J. Sports Reh. Po.*; 2020. : 7 : 1 ; 1450-1478.
38. J. Van de Rakt. *Collumfractuur en peroneusparesse*. *Tijdschrift voor fysiotherapie*.1980. . 6e nummer. 86.
39. T. Husain. *Pressure sores*. *J.Path Baet LX.V.T. J Pathol Bacteriol* 1953;66(2):347–58



40. H. Bogaardt, D. Dam. N. Van Wever , C. Bruggeman. J. Koops J. & W. Fokkens. *The use of neuromusculair electrostimulation in the treatment of dyphagia in patients with multipele sclerosis. Annals of Otology Rhinology & Laryngology.* 2009.

41. Bogaardt, H.C.A.. *Electrical stimulation in dysphagia treatment: a justified controversy.* 2008. *B-ENT* 4: 61-65,

42. Crary, M.A., Carnaby-Mann, G.D, Groher, M.E., Helseth, E. *Functional Benefits of Dysphagia Therapy Using Adjunctive sEMG Biofeedback.* 2004. *Dysphagia*, 2004. 4 Summer;19(3):160-4.

1781

43. Steele, C.M., Bennett, J.W., Chapman-Jay, S., Polacco, R.C., Molfenter, S.M., Oshalla, M. *Electromyography as a Biofeedback Tool for Rehabilitating Swallowing Muscle Function. Applications of emg in Clinical and Sports Medicine.* 2012. *InTech Publishing* , 311-328

44. Bohannon R.W. Suith M.B. *Interrater reliability of a modified Ashworth scale of muscle spasticity* *Phys.Ther.* 1987. 1987 Feb;67(2):206-7.


45. Waardenburg H. en anderen. *Is paratonie betrouwbaar te meten ?* *Ned.Tijdsch.v. Fysiother* 2006;116(5):117-122

46. Kenzo Kase *Illustrated kinesio-taping.ed.* Ken'i-Kai Tokyo 1994 ISBN 1880047241





Info Scientific article



Jan van de Rakt, Steve McCarthy-Grunwald,

**Swallowing and the attitude of the neck/body !**

*Ita. J. Sports Reh. Po. 2021; 8 (17); 2;1; 1745 – 1783 ; DOI: 10.17385/ItaJSRP.21.17.080201 ;*

*ISSN 2385-1988 [online] IBSN 007-111-19 - 55; CGI J OAJI 0,101]. Published online.*

Corresponding Author



Corresponding author

**Jan van de Rakt**

Physical Therapist NDT teacher IBITA, Course Leader and teacher on the Dutch Institute for Allied Health Sciences .  
Nursing Home “Waelwick” in Ewijk The Netherlands

**e mail address : [jan@vanderakt.nl](mailto:jan@vanderakt.nl)**

Declaration of interest

The authors declare that they have no financial, consulting, and personal relationships with other people or organizations that could influence the author's work.

Author's Contributions

**Authorship credit :** “Criteria authorship scientific article” has been used “Equal Contribution” (EC)  
All authors played a significant role in this project; All authors were involved in drafting the manuscript critically for important content, and all authors approved the final version.

Info Journal



**Publication Start Year :** 2014

**Country of Publication:** Italy

**Title Abbreviation:** Ita. J. Sports Reh. Po.

**Language :** Italian/ English

**Publication Type(s) :** No Periodical

**Open Access Journal :** Free

**ISSN :** 2385-1988 [Online]

**IBSN :** 007-111-19-55

**DOI :** Digital object identifier

**ISI Impact Factor:** CGIJ OAJI :0,101

**Index/website :** Open Academic Journals Index , [www.oaji.net/](http://www.oaji.net/)

Google Scholar – Google Citations

[www.facebook.com/Ita.J.Sports.Reh.Po](https://www.facebook.com/Ita.J.Sports.Reh.Po)

**Info:** [journalsportsrehabilitation@gmail.com](mailto:journalsportsrehabilitation@gmail.com)



1783

